

Iliopsoas

Pathology, Diagnosis, and Treatment



Christian N. Anderson, MD

KEYWORDS

- Iliopsoas • Psoas • Coxa saltans interna • Snapping hip • Iliopsoas bursitis
- Iliopsoas tendinitis • Iliopsoas impingement

KEY POINTS

- The iliopsoas musculotendinous unit is a powerful hip flexor used for normal lower extremity function, but disorders of the iliopsoas can be a significant source of groin pain in the athletic population.
- Arthroscopic release of the iliopsoas tendon and treatment of coexisting intra-articular abnormality is effective for patients with painful iliopsoas snapping or impingement that is refractory to conservative treatment.
- Tendon release has been described at 3 locations: in the central compartment, the peripheral compartment, and at the lesser trochanter, with similar outcomes observed between the techniques.
- Releasing the tendon lengthens the musculotendinous unit, resulting in transient hip flexor weakness that typically resolves by 3 to 6 months postoperatively.

INTRODUCTION

The iliopsoas musculotendinous unit is a powerful hip flexor that is important for normal hip strength and function. Even so, pathologic conditions of the iliopsoas have been implicated as a significant source of anterior hip pain. Iliopsoas disorders have been shown to be the primary cause of chronic groin pain in 12% to 36% of athletes and are observed in 25% to 30% of athletes presenting with an acute groin injury.^{1–4} Described pathologic conditions include iliopsoas bursitis, tendonitis, impingement, and snapping. Acute trauma may result in injury to the musculotendinous unit or avulsion fracture of the lesser trochanter. Developing an understanding of the anatomy and function of the musculotendinous unit is necessary to accurately determine the diagnosis and formulate an appropriate treatment strategy for disorders of the iliopsoas.

Disclosure: The author has nothing to disclose.

Tennessee Orthopaedic Alliance, The Lipscomb Clinic, Saint Thomas West Hospital, Medical Plaza East, Suite 1000, 4230 Harding Road, Nashville, TN 37205, USA

E-mail address: andersoncn@toa.com

Clin Sports Med 35 (2016) 419–433

<http://dx.doi.org/10.1016/j.csm.2016.02.009>

sportsmed.theclinics.com

0278-5919/16/\$ – see front matter © 2016 Elsevier Inc. All rights reserved.

ANATOMY AND FUNCTION

The iliopsoas tendon-muscle complex is composed of 3 muscles: the iliacus, psoas major, and psoas minor (**Fig. 1**).⁵ The psoas major is a long fusiform muscle that originates on the vertebral bodies, transverse processes, and intervertebral disks of T12-L5.^{5,6} The iliacus is a triangular fan-shaped muscle that is composed of medial and lateral bundles and originates from the ventral lip of the iliac crest, superior two-thirds of the iliac fossa, and sacral ala.⁵⁻⁸ A third, smaller bundle, known as the ilio-infratrochanteric muscle, has been observed lateral to the lateral iliacus.^{8,9} Innervation of the psoas major and iliacus are from the ventral rami of L1-3 and femoral nerve (L1-2), respectively.⁵

The psoas major and iliacus muscles converge at the level of the L5 to S2 vertebrae to form the iliopsoas muscle.⁹ Before this convergence, the psoas major tendon originates above the level of the inguinal ligament from within the center of the psoas major muscle.⁹ As the tendon courses distally, it rotates clockwise (right hip) and migrates posteriorly within the muscle, lying immediately anterior to the hip joint, and inserts directly on the lesser trochanter (**Fig. 2**).⁹

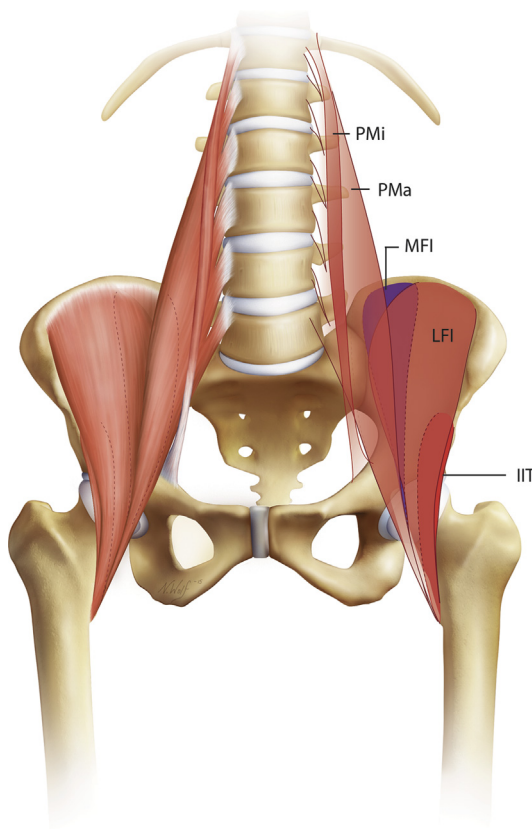


Fig. 1. AP anatomy of the iliopsoas musculotendinous unit as described by Tatu and colleagues⁹ and Guillin and colleagues.⁸ IIT, ilio-infratrochanteric muscle; LFI, lateral fibers of the iliacus; MFI, medial fibers of the iliacus; PMa, psoas major; PMi, psoas minor.

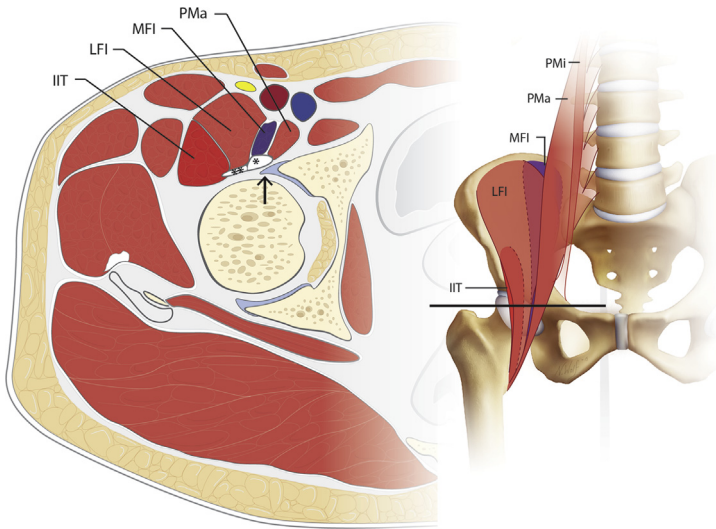


Fig. 2. Cross-sectional anatomy of the iliopsoas through the hip joint as described by Tatu and colleagues⁹ and Guillin and colleagues.⁸ The plane (*black line*) is demonstrated on the AP image. At this level, the iliacus (*double asterisk*) and psoas (*asterisk*) tendons are posterior to the iliopsoas muscle bundles and anterior to the hip joint and labrum (*arrow*).

Significant anatomic variability of the iliopsoas musculotendinous unit has been reported in the literature.^{6,9–12} In a cadaveric study, Tatu and colleagues⁹ reported the presence of 2 tendinous structures: the psoas major and iliacus tendons. The medial iliacus muscle bundle was shown to insert onto the iliacus tendon, which progressively converges with the larger and more medial psoas major tendon.⁹ The lateral muscle bundle of the iliacus courses distally, without any tendinous attachments, and inserts on the anterior surface of the lesser trochanter and infratrochanteric ridge.⁹ These findings were corroborated in a study by Guillin and colleagues⁸ using ultrasound (US) to map the iliopsoas anatomy. Conversely, in a study using MRI with cadaveric correlation, Polster and coworkers¹⁰ noted the medial iliacus bundle merged directly into the psoas major tendon, whereas the medial-most fibers of the lateral iliacus bundle inserted on a distinct thin intramuscular tendon. Philippon and colleagues⁶ examined 53 fresh frozen cadavers and demonstrated at the level of the hip joint the prevalence of a single-, double-, and triple-banded iliopsoas tendon was noted 28.3%, 64.2%, and 7.5% of the time, respectively. In the pediatric population, the presence of 2 distinct tendons was observed in 21% of patients undergoing MRI.¹¹ Although controversy exists regarding the number of tendons and the relative contributions of the different muscle fibers to each tendon, the current literature challenges historical descriptions of a single common conjoint tendon.

The iliopsoas bursa, also known as the iliopectineal bursa, is positioned between the musculotendinous unit and the bony surfaces of the pelvis and proximal femur. It has been shown to be the largest bursa in the human body, typically extending from the iliopectineal eminence to the lower portion of the femoral head, with an average length of 5 to 6 cm and width of 3 cm.⁹ Reports of communication of the bursa with the hip joint, through a congenital defect between the iliofemoral and pubofemoral ligaments, are variable. Tatu and colleagues⁹ reported no communication in 14 cadaveric dissections; however, others have observed a direct communication

between the joint and bursa in 15% of patients.¹³ It is important to consider this communication during diagnostic injections, because the anesthetic material can move between the intra-articular and bursal compartments, confounding the results of the test.

The iliopsoas unit functions primarily as a powerful hip flexor, but also has important function in femoral external rotation and with lateral bending, flexion, and balance of the trunk.^{14–17} The iliacus and psoas major have been shown to have individual and task-specific activation patterns.^{14,16} The iliacus is important for stabilizing the pelvis¹⁶ and for early rapid hip flexion while running.¹⁴ The psoas major is important for sitting in an erect position and stability of the spine in the frontal plane.¹⁶ Variable contribution of each muscle is observed during sit-ups depending on the angle of hip flexion.¹⁶

The psoas minor is a long slender muscle that originates from the vertebral bodies of T12 and L1 and is only present in 60% to 65% of individuals.^{18,19} Distally, it merges with the iliac fascia and psoas major tendon, and in 90% of specimens, it has a firm bony attachment to the iliopectineal eminence.¹⁹ The attachment to both the iliac fascia and the bony pelvis may assist in partially controlling the position and mechanical stability of the underlying iliopsoas as it crosses the femoral head.¹⁹

ILIOPSOAS SNAPPING

Iliopsoas snapping, also known as coxa saltans interna or internal hip snapping, is a disorder characterized by painful audible or palpable snapping of the iliopsoas during hip movement. Symptomatic snapping most commonly occurs with activities or sports that require significant hip range-of-motion, such as dance, soccer, hockey, and football,^{20,21} and is observed more commonly in girls and women than in boys and men.²² A history of acute trauma has been associated with the development of snapping in up to 50% of cases.²³ Although the true prevalence of this disorder is unknown, symptomatic snapping has been observed in up to 58% of elite ballet dancers.²¹ Even so, the prevalence of asymptomatic snapping in the general population has been shown to be as high as 40%.⁸ Therefore, careful assessment is important to determine if the snapping is symptomatic before proceeding with a treatment plan.

Snapping Mechanism

In 1951, Nunziata and Blumenfeld²⁴ first described the mechanism of internal coxa saltans as snapping of the iliopsoas tendon over the iliopectineal eminence of the pelvis. Since then, dynamic US has been used in several studies to confirm this mechanism as the primary source of iliopsoas snapping.^{21,23,25–27} Most studies report a sudden “jerky” movement and audible or palpable snap of the iliopsoas over the iliopectineal eminence as the hip is brought from a position of flexion, abduction, and external rotation (FABER) to extension and neutral.

Although abnormal movement of the tendon over the iliopectineal eminence is commonly described as the source of the snapping phenomena, alternative mechanisms have been proposed. Several studies propose that soft tissue abnormalities, such as an accessory iliopsoas tendinous slip,²⁸ a paralabral cyst,²⁸ and/or stenosing tenosynovitis, are the source of snapping.²⁹ Other investigators have determined the iliopsoas snapping occurs over a bony prominence other than the iliopectineal eminence, such as the lesser trochanter¹³ or the femoral head.³⁰ More recently, dynamic US has been used to demonstrate a sudden flipping of the psoas tendon over the iliacus muscle as the source of snapping.^{8,21,28} In these studies, as the hip was flexed, abducted, and externally rotated, the iliacus became interposed between the psoas tendon and the superior pubic rami. As the hip was brought to neutral, part of

the medial iliacus muscle became trapped as the tendon followed a reverse path to its original position. The trapped iliacus is suddenly released, resulting in an audible snap of the tendon against the pubic bone. Contrary to the original mechanism described by Nunziata and Blumenfeld, the iliopectineal eminence was medial to the psoas tendon and not involved with the observed snapping phenomena.²⁸ Overall, the exact mechanism of snapping remains controversial, and the lack of consensus regarding the mechanism supports the possibility of several potential causes for iliopsoas snapping.

Iliopsoas Bursitis and Tendonitis

Iliopsoas bursitis and tendonitis have been shown to be closely associated with the repetitive pathologic movement of the tendon observed in symptomatic coxa saltans interna.^{13,26,31,32} The irregular movement of the tendon during the snapping phenomenon is thought to cause irritation and inflammation of the underlying bursa.^{33–35} Even so, some studies demonstrate no objective abnormality of the bursa in patients undergoing open surgery for symptomatic snapping.^{13,36} Nevertheless, these conditions coexist so frequently that Johnston and coworkers³¹ suggested they be considered a single entity referred to as “iliopsoas syndrome.” Correspondingly, the diagnostic workup and treatment for these conditions are the same.

History and Physical Examination

The diagnosis of iliopsoas snapping begins with a thorough history. Patients often report painful snapping with hip movement during sporting or recreational activities. Patients may also have pre-existing asymptomatic snapping that becomes painful after repetitive training activities involving high hip flexion angles.²⁰ Symptoms can also occur during activities of daily living such as climbing stairs or standing from a sitting position.³⁷ The snapping sensation is accompanied by groin pain that may radiate into the thigh or top of the knee.

Physical examination should include a complete musculoskeletal evaluation of the hip and focused specialty tests specific for the suspected diagnosis. The most commonly described examination maneuver for detecting internal hip snapping is what is referred to as the “active iliopsoas snapping test.” This test is performed by having the patient actively move the hip from the FABER position to extension and neutral (**Fig. 3**). The examiner’s hand should be placed on the groin to palpate the iliopsoas snapping, which typically occurs with the hip at between 30° and 45° of flexion.³⁸ Iliopsoas strength is assessed by resisted hip flexion with the patient in the sitting position. Testing in this manner may also result in groin pain, but does not usually recreate snapping. Localized swelling of the inguinal region has been reported in up to 59% of patients with painful internal snapping.²⁶

It is paramount to also evaluate the patient for external snapping of the iliotibial band (ITB) over the greater trochanter, which may present in a similar manner to iliopsoas snapping. Patients often report a sensation of the hip dislocating during the snapping event. The examination is the most efficient way to distinguish between internal and external hip snapping. The author’s preferred examination technique, the “bicycle test,” for determining the presence of external hip snapping is performed by having the patient actively cycle the affected extremity from flexion to extension while lying in the lateral decubitus position (**Fig. 4**). A palpable snap or clunk over the greater trochanter is confirmatory for this diagnosis.

Imaging

Although iliopsoas snapping is typically diagnosed with a thorough history and physical examination, imaging studies can be valuable for confirming the diagnosis and

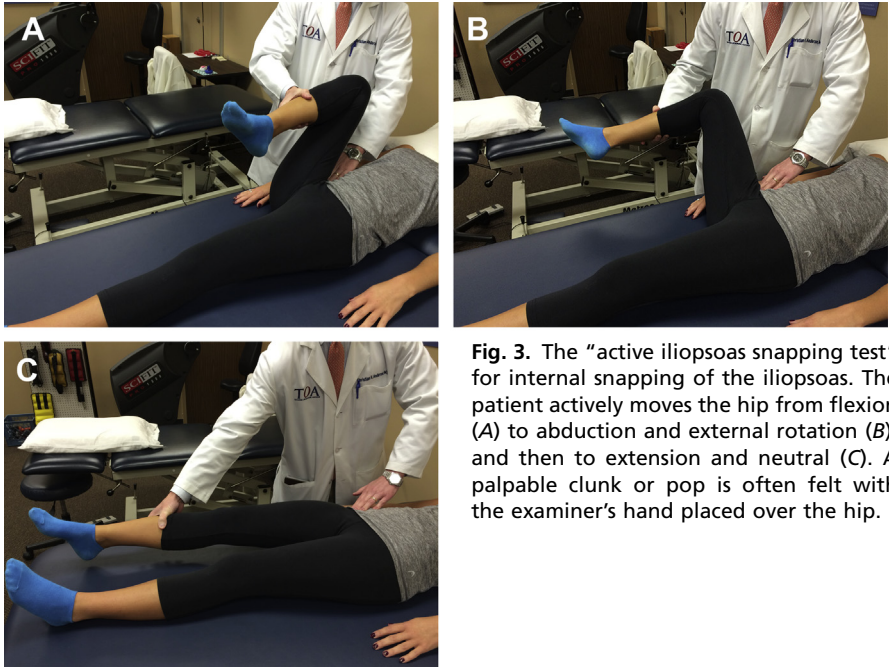


Fig. 3. The “active iliopsoas snapping test” for internal snapping of the iliopsoas. The patient actively moves the hip from flexion (A) to abduction and external rotation (B), and then to extension and neutral (C). A palpable clunk or pop is often felt with the examiner’s hand placed over the hip.

identifying concomitant hip abnormality. Radiographic evaluation should begin with anteroposterior (AP) pelvis and lateral hip radiographs to rule out acute or chronic osseous abnormalities and to evaluate for radiographic signs of femoroacetabular impingement (FAI). In cases wherein the source of snapping is uncertain, dynamic US can be used to visualize the iliopsoas tendon or ITB during provocative maneuvers, such as the active iliopsoas snapping and bicycle tests.^{8,21,23,25–28,32} US is also useful in identifying joint effusions and synovitis, rectus femoris tendinopathy, and iliopsoas bursitis and tendonitis.^{26,32} In addition to also being able to detect iliopsoas tendinitis and bursitis,²³ MRI is useful in diagnosing associated chondral and labral abnormality, which are present in 67% to 100% of patients presenting with painful iliopsoas

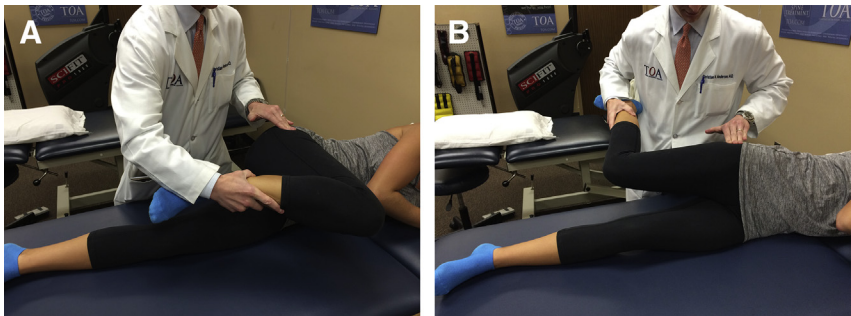


Fig. 4. The “bicycle test” for external snapping of the ITB. In the lateral decubitus position, the patient actively flexes (A) and then extends (B) the hip. A palpable, audible, and/or visible clunk can be detected over the greater trochanter.

snapping.^{39–42} MRI can also determine the pathologic reason for snapping in up to 100% of patients.²⁶ In addition to formal imaging, US-guided injections of the iliopsoas bursa are useful in the evaluation of iliopsoas snapping (**Fig. 5**).⁴³ A preinjection and postinjection examination can be performed to determine if the patient experiences pain relief, and if so, supports the diagnosis of painful snapping.³⁹

Surgical Treatment

Surgical treatment is considered in patients that have failed at least 3 months of a dedicated conservative program, including activity modification, physical therapy, nonsteroidal anti-inflammatory drugs (NSAIDs), and corticosteroid injections. The goal of surgical treatment is to lengthen the iliopsoas musculotendinous unit to prevent snapping and mechanical overpressurization of the underlying bursa.

Various techniques have been developed to release or lengthen the iliopsoas tendon. Historically, open surgery has been used; however, these procedures have increased morbidity and inferior results compared with arthroscopic techniques. In a systematic review of 11 studies, Khan and colleagues⁴⁴ demonstrated a complication rate of 21% in open procedures compared with 2.3% using arthroscopic techniques. Furthermore, patients undergoing open procedures had more postoperative pain, and recurrent snapping occurred in 23% of open compared with 0% of the arthroscopic surgeries.⁴⁴ In addition to lower complications and recurrent snapping, the arthroscopic approach can be used to diagnose and treat concomitant intra-articular abnormality. Treatment of associated intra-articular abnormalities in conjunction with iliopsoas snapping may result in improved patient-reported outcomes (PROs) relative to open procedures. Currently, however, there are no direct comparative studies evaluating open versus arthroscopic techniques for iliopsoas lengthening.

Arthroscopic release of the iliopsoas tendon has been described at 3 locations (**Fig. 6**): in the central compartment (**Fig. 7**),^{40,41,45,46} in the peripheral compartment

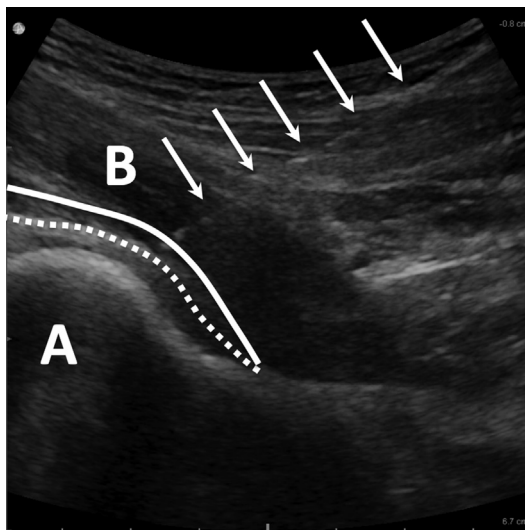


Fig. 5. US-guided injection of the iliopsoas bursa demonstrating the needle trajectory (arrows) toward the femoral head (A). The tip of the needle should penetrate through the iliopsoas muscle (B) into the iliopsoas bursa, which is located between the posterior surface of the iliopsoas (solid line) and the joint capsule (dashed line).

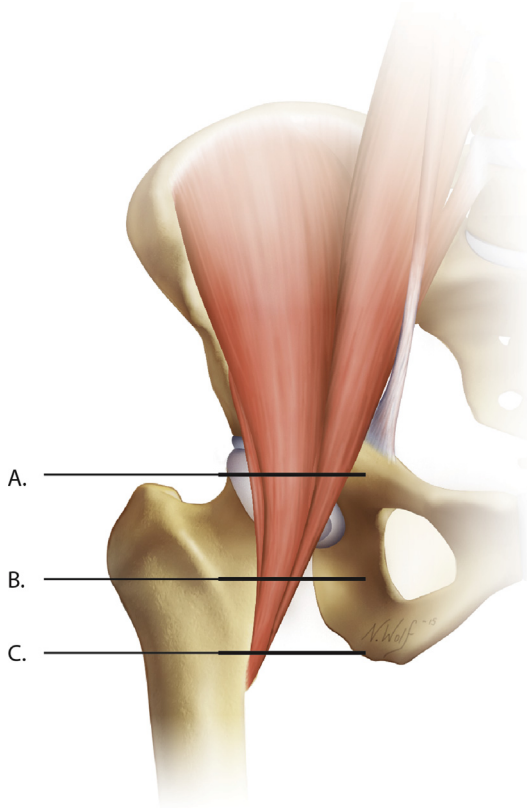


Fig. 6. The 3 described levels of iliopsoas release: central compartment (A), peripheral compartment (B), and lesser trochanter (C). At these levels, the ratio of tendon to muscle is 40% tendon/60% muscle belly, 53% tendon/47% muscle belly, and 60% tendon/40% muscle belly, respectively.

(Fig. 8),^{47,48} and at the lesser trochanter (Fig. 9).^{39,42,49,50} Level IV case series studies evaluating these techniques universally report good/excellent PROs, low recurrence rates, and minimal complications.^{39–42,45–48} In a study evaluating athletes with painful iliopsoas snapping, Anderson and Keene³⁹ reported return to sport in all patients at an average of 9 months after release of the tendon at the lesser trochanter. In a level I randomized trial and a level IV comparative study, Ilizaliturri and colleagues^{51,52} found favorable results with iliopsoas release either at the lesser trochanter or in the central compartment, with no significant differences between the techniques.

Although outcomes are generally good, transient weakness^{39,41,42,47,48,50,52} and atrophy of the iliopsoas on MRI⁵³ have been observed after tenotomy. Even so, complete resolution of the weakness typically occurs by 3 to 6 months after surgery,^{39,41,42} and no significant differences in hip flexion strength have been observed with tendon release at the different described levels.^{44,51,52} The latter observation can partly be explained by the similar ratio of muscle to tendon volume observed at these locations.⁵⁴ Consequently, each technique results in a comparable volume of muscle fibers remaining intact within the musculotendinous unit, allowing similar forces to be generated for hip flexion.

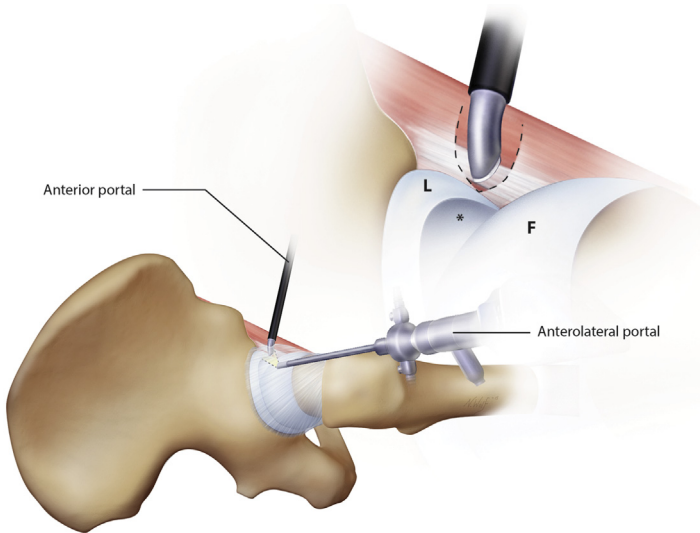


Fig. 7. Release of the iliopsoas tendon in the central compartment. With the hip under traction, a 70° arthroscope is placed in the anterolateral portal for visualization, and a beaver blade is used to extend the interportal capsulotomy medially (*dashed line*) to expose the iliopsoas tendon, located just anterior to the iliopsoas notch at the 3 o'clock position on the acetabulum (*asterisk*). The tendon can then be released with the blade or an electrocautery device, taking care to leave the muscular portion of iliopsoas intact, resulting in a fractional lengthening of the musculotendinous unit. F, femoral head; L, labrum.

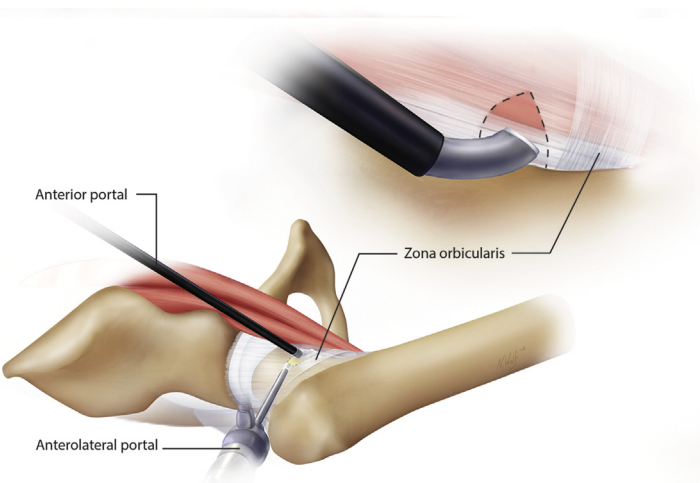


Fig. 8. Iliopsoas tenotomy in the peripheral compartment. To facilitate visualization, traction is released and the hip is placed in 30° of flexion. A 30° arthroscope is placed in the anterolateral portal and pointed anteriorly toward the joint capsule. The iliopsoas tendon can be identified through a small (1 cm) transverse capsulotomy (*dashed line*) lateral to the medial synovial fold and just proximal to the zona orbicularis anteriorly. An electrocautery device or beaver blade can then be used to divide the tendon.

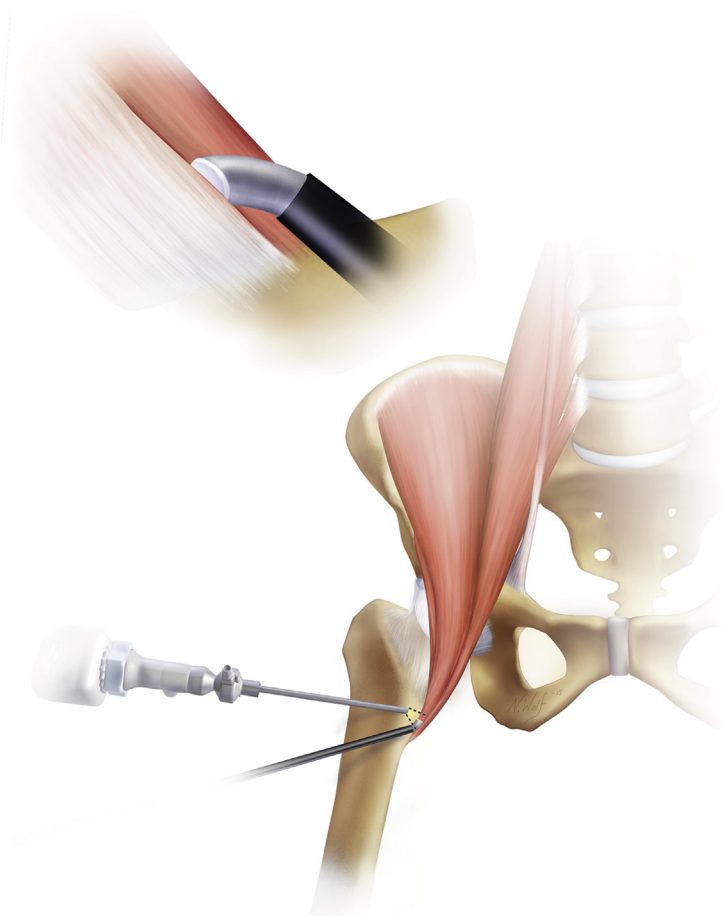


Fig. 9. Iliopsoas tendon release at the lesser trochanter. To access the lesser trochanter, the hip is flexed 30° and externally rotated until the lesser trochanter is parallel to the coronal plane of the body and maximally visualized with fluoroscopy. A spinal needle is then advanced anterior and perpendicular to the femur until it reaches the lesser trochanter. A cannula is placed in this position, and a second portal is made in a similar manner 5 to 7 cm distal to the first one. The 30° arthroscope is then placed in the proximal portal and electrocautery is used in the distal portal to clear any soft tissues and release the iliopsoas tendon at its insertion on the lesser trochanter.

Further studies have evaluated variables that are predictors of worse clinical outcomes.^{40,46} In a level IV case series by Bitar and coworkers,⁴⁰ patients with recurrent snapping (18%) after iliopsoas lengthening in the central compartment had no improvements in PROs and had lower satisfaction and worse outcomes compared with those with resolution of snapping. In a separate level IV case series, Fabricant and colleagues⁴⁶ studied 67 consecutive patients undergoing iliopsoas release in the central compartment and determined patients with high femoral anteversion (>25°) had lower modified Harris hip scores (HHS) compared with patients that had normal to low ($\leq 25^\circ$) femoral anteversion. They hypothesized that the iliopsoas may act as an important dynamic stabilizer given its anatomic location at the anterior aspect of the hip joint.⁴⁶ Overall, additional research is necessary to determine the

best technique of iliopsoas release and further predictors of functional outcome and PROs.

ILIOPSOAS IMPINGEMENT

First described by Heyworth and colleagues⁵⁵ in 2007, iliopsoas impingement (IPI) is a pathomechanical process whereby an excessively tight iliopsoas tendon impinges on the underlying acetabular labrum, resulting in characteristic labral abnormality at the location of the psoas tendon on the acetabular rim. In this initial report, the investigators noted IPI and corresponding labral injury in 7 of 24 revision hip arthroscopy cases.⁵⁵ In each case, after iliopsoas release at the level of the acetabulum, the tendon no longer impinged on the anterior labrum during hip extension.⁵⁵ In a follow-up study at the same institution, Domb and coworkers⁵⁶ further defined the pathophysiologic mechanism of this phenomenon. In this study, the investigators identified 25 patients with direct anterior labral tears at the 3 o'clock position (right hip) in the absence of bony abnormalities. The location of labral abnormality corresponded to the iliopsoas notch (Fig. 10), directly beneath the iliopsoas tendon, which significantly differs from the traditional 1 to 2 o'clock location observed in FAI.^{57,58} In some cases, the labrum appeared inflamed without frank tearing, which was referred to as the "IPI sign." Furthermore, adjacent tendinous inflammation and scarring of the tendon to the anterior capsule were observed in some patients. The investigators concluded that the labral injury was possibly the result of a tight iliopsoas impinging on the anterior labrum or a repetitive traction injury to the labrum from adherence of the tendon to the adjacent capsulolabral complex. Similar to the observations of Heyworth and colleagues, Domb and coworkers found releasing the tendon decreased compression on the underlying labrum in all cases. A cadaveric study by Yoshio and colleagues⁵⁹ demonstrated maximal pressure underneath the iliopsoas tendon occurs at the joint level during hip extension, supporting the possibility that excessive pathologic forces from the iliopsoas possibly results in labral injury.

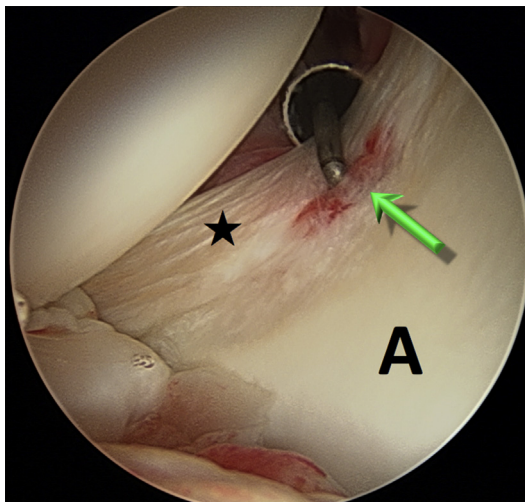


Fig. 10. Arthroscopic view from the posterolateral portal of a labral tear at the 3 o'clock position (*arrow*) in a patient with IPI. The iliopsoas notch, anterior labrum (*star*), and anterior acetabulum (*A*) are well visualized from this portal.

Iliopsoas impingement occurs most frequently in young active women, many who participate in regular sports.^{45,56,60,61} Patients typically present with anterior groin pain that worsens with athletic activities and activities of daily living, such as active hip flexion, prolonged sitting, and getting out of a car.^{45,56,60} Iliopsoas snapping is less commonly observed in IPI but has been reported in up to 17% of cases.^{45,60} On physical examination, patients typically have a positive impingement test (flexion, adduction, and internal rotation), scour sign (flexion, adduction, and axial compression), and tenderness with manual compression over the iliopsoas.^{45,56,60} Approximately half of the patients have pain with FABER and resisted straight leg-raise testing.^{45,60} Intra-articular injections have shown variable results with some studies reporting transient improvement in 50% of patients,⁵⁶ whereas other studies report improved symptoms in all patients undergoing injection.⁶⁰ Plain film radiographs may show signs of FAI⁴⁵; however, the most pertinent radiographic finding is a labral tear at or near the 3 o'clock position seen on MRI.⁶⁰

Surgical management of IPI focuses on lengthening of the iliopsoas tendon and treatment of concurrent labral abnormality. Several studies have demonstrated favorable results with this treatment plan.^{45,56,61} In the study by Domb and colleagues,⁵⁶ at an average of 21 months after arthroscopic tendon lengthening and either labral debridement or repair, 95% of patients surveyed reported their physical ability as “much improved” and none reported worse symptoms. HHS and hip outcome scores were available in 8 patients at final follow-up and demonstrated significant improvements compared with preoperative scores. Cascio and colleagues⁶¹ reported on 16 hips with a minimum of 6-months follow-up that underwent tendon lengthening, with or without labral repair. The investigators noted the HHS improved from a mean of 70 preoperatively to 94 postoperatively; however, one patient required revision surgery at 18 months for repair of a labral tear that was not addressed at the initial surgery. Nelson and Keene⁴⁵ reported good to excellent results (modified HHS ≥ 80 points) in 23 of 30 patients undergoing tendon release for IPI. Patients with lower final PROs had avascular necrosis ($n = 1$), progressive degenerative joint disease ($n = 1$), trochanteric bursitis ($n = 2$), or recurrent painful iliopsoas snapping ($n = 3$). Two of the 3 patients with recurrent symptomatic snapping underwent a second iliopsoas release at the lesser trochanter and subsequently demonstrated good to excellent outcomes 1 year after the revision surgery. Although these level IV reports are encouraging, further studies with long-term follow-up are necessary to determine optimal treatment for IPI.

SUMMARY

The iliopsoas is an anatomically complex musculotendinous unit that functions primarily as a powerful hip flexor and secondarily as a femoral rotator and stabilizer of the lumbar spine and pelvis. Commonly described pathologic conditions of the involved tendon-muscle complex include iliopsoas bursitis, tendonitis, impingement, and snapping. Initial treatment of iliopsoas disorders generally consists of a combination of physical therapy, activity modification, NSAIDs, and corticosteroid injections. If conservative treatment fails, arthroscopic surgery to address the existing pathologic condition has demonstrated encouraging results in mostly level IV studies. Further studies with a higher level of evidence and longer follow-up are needed to determine optimal treatments for these conditions.

REFERENCES

1. Serner A, Tol JL, Jomaah N, et al. Diagnosis of acute groin injuries: a prospective study of 110 athletes. *Am J Sports Med* 2015;43(8):1857–64.

2. Holmich P, Renstrom PA. Long-standing groin pain in sportspeople falls into three primary patterns, a “clinical entity” approach: a prospective study of 207 patients. *Br J Sports Med* 2007;41(4):247–52.
3. Holmich P, Thorborg K, Dehlendorff C, et al. Incidence and clinical presentation of groin injuries in sub-elite male soccer. *Br J Sports Med* 2014;48(16):1245–50.
4. Rankin AT, Bleakley CM, Cullen M. Hip joint pathology as a leading cause of groin pain in the sporting population: a 6-year review of 894 cases. *Am J Sports Med* 2015;43(7):1698–703.
5. Moore KL, Dalley AF. Clinically oriented anatomy. 4th edition. Baltimore (MD): Lippincott Williams & Wilkins; 1999. p. 533.
6. Philippon MJ, Devitt BM, Campbell KJ, et al. Anatomic variance of the iliopsoas tendon. *Am J Sports Med* 2014;42(4):807–11.
7. Lee K, Rosas H, Phancao JP. Snapping hip: imaging and treatment. *Semin Musculoskelet Radiol* 2013;17(03):286–94.
8. Guillin R, Cardinal É, Bureau NJ. Sonographic anatomy and dynamic study of the normal iliopsoas musculotendinous junction. *Eur Radiol* 2008;19(4):995–1001.
9. Tatu L, Parratte B, Vuillier F, et al. Descriptive anatomy of the femoral portion of the iliopsoas muscle. *Anatomical basis of anterior snapping of the hip. Surg Radiol Anat* 2001;23(6):371–4.
10. Polster JM, Elgabaly M, Lee H, et al. MRI and gross anatomy of the iliopsoas tendon complex. *Skeletal Radiol* 2007;37(1):55–8.
11. Crompton T, Lloyd C, Kokkinakis M, et al. The prevalence of bifid iliopsoas tendon on MRI in children. *J Child Orthop* 2014;8(4):333–6.
12. Shu B, Safran MR. Case report: bifid iliopsoas tendon causing refractory internal snapping hip. *Clin Orthop Relat Res* 2010;469(1):289–93.
13. Schaberg JE, Harper MC, Allen WC. The snapping hip syndrome. *Am J Sports Med* 1984;12(5):361–5.
14. Mann RA, Moran GT, Dougherty SE. Comparative electromyography of the lower extremity in jogging, running, and sprinting. *Am J Sports Med* 1986;14(6):501–10.
15. Fitzgerald P. The action of the iliopsoas muscle. *Ir J Med Sci* 1969;8(1):31–3.
16. Andersson E, Oddsson L, Grundström H, et al. The role of the psoas and iliacus muscles for stability and movement of the lumbar spine, pelvis and hip. *Scand J Med Sci Sports* 1995;5(1):10–6.
17. Rajendran K. The insertion of the iliopsoas as a design favouring lateral rather than medial rotation at the hip joint. *Singapore Med J* 1989;30(5):451–2.
18. Clemente CD. Anatomy: a regional atlas of the human body. 4th edition. Baltimore (MD): Lippincott Williams & Wilkins; 1997. p. 363.
19. Neumann DA, Garceau LR. A proposed novel function of the psoas minor revealed through cadaver dissection. *Clin Anat* 2014;28(2):243–52.
20. Wahl CJ, Warren RF, Adler RS, et al. Internal coxa saltans (snapping hip) as a result of overtraining: a report of 3 cases in professional athletes with a review of causes and the role of ultrasound in early diagnosis and management. *Am J Sports Med* 2004;32(5):1302–9.
21. Winston P, Awan R, Cassidy JD, et al. Clinical examination and ultrasound of self-reported snapping hip syndrome in elite ballet dancers. *Am J Sports Med* 2006;35(1):118–26.
22. Kroger E, Griesser M, Kolovich G, et al. Efficacy of surgery for internal snapping hip. *Int J Sports Med* 2013;34(10):851–5.
23. Janzen DL, Partridge E, Logan PM, et al. The snapping hip: clinical and imaging findings in transient subluxation of the iliopsoas tendon. *Can Assoc Radiol J* 1996;47(3):202–8.

24. Nunziata A, Blumenfeld I. Cadera a resorte: a proposito de una variedad. *Prensa Med Argent* 1951;38(32):1997–2001.
25. Cardinal E, Buckwalter KA, Capello WN, et al. US of the snapping iliopsoas tendon. *Radiology* 1996;198(2):521–2.
26. Wunderbaldinger P, Bremer C, Matuszewski L, et al. Efficient radiological assessment of the internal snapping hip syndrome. *Eur Radiol* 2001;11(9):1743–7.
27. Hashimoto BE, Green TM, Wiitala L. Ultrasonographic diagnosis of hip snapping related to iliopsoas tendon. *J Ultrasound Med* 1997;16(6):433–5.
28. Deslandes M, Guillin R, Cardinal E. The snapping iliopsoas tendon: new mechanisms using dynamic sonography. *AJR Am J Roentgenol* 2008;190(3):576–81.
29. Micheli LJ. Overuse injuries in children's sports: the growth factor. *Orthop Clin North Am* 1983;14(2):337–60.
30. Howse AJ. Orthopaedists aid ballet. *Clin Orthop Relat Res* 1972;89:52–63.
31. Johnston CA, Wiley JP, Lindsay DM, et al. Iliopsoas bursitis and tendinitis. A review. *Sports Med* 1998;25(4):271–83.
32. Pelsser V, Cardinal E, Hobden R, et al. Extraarticular snapping hip: sonographic findings. *AJR Am J Roentgenol* 2001;176(1):67–73.
33. Staple TW. Arthrographic demonstration of iliopsoas bursa extension of the hip joint. *Radiology* 1972;102(3):515–6.
34. Penkava RR. Iliopsoas bursitis demonstrated by computed tomography. *AJR Am J Roentgenol* 1980;135(1):175–6.
35. Peters JC, Coleman BG, Turner ML. CT evaluation of enlarged iliopsoas bursa. *AJR Am J Roentgenol* 1980;135(2):392–4.
36. Jacobson T, Allen WC. Surgical correction of the snapping iliopsoas tendon. *Am J Sports Med* 1990;18(5):470–4.
37. Ilizaliturri VM Jr, Camacho-Galindo J. Endoscopic treatment of snapping hips, iliotibial band, and iliopsoas tendon. *Sports Med Arthrosc* 2010;18(2):120–7.
38. Sammarco GJ. The dancer's hip. *Clin Sports Med* 1983;2(3):485–98.
39. Anderson SA, Keene JS. Results of arthroscopic iliopsoas tendon release in competitive and recreational athletes. *Am J Sports Med* 2008;36(12):2363–71.
40. Bitar El YF, Stake CE, Dunne KF, et al. Arthroscopic iliopsoas fractional lengthening for internal snapping of the hip: clinical outcomes with a minimum 2-year follow-up. *Am J Sports Med* 2014;42(7):1696–703.
41. Contreras ME, Dani WS, Endges WK, et al. Arthroscopic treatment of the snapping iliopsoas tendon through the central compartment of the hip: a pilot study. *J Bone Joint Surg Br* 2010;92(6):777–80.
42. Flanum ME, Keene JS, Blankenbaker DG, et al. Arthroscopic treatment of the painful "internal" snapping hip: results of a new endoscopic technique and imaging protocol. *Am J Sports Med* 2007;35(5):770–9.
43. Blankenbaker DG, De Smet AA, Keene JS. Sonography of the iliopsoas tendon and injection of the iliopsoas bursa for diagnosis and management of the painful snapping hip. *Skeletal Radiol* 2006;35(8):565–71.
44. Khan M, Adamich J, Simunovic N. Surgical management of internal snapping hip syndrome: a systematic review evaluating open and arthroscopic approaches. *Arthroscopy* 2013;29(5):942–8.
45. Nelson IR, Keene JS. Results of labral-level arthroscopic iliopsoas tenotomies for the treatment of labral impingement. *Arthroscopy* 2014;30(6):688–94.
46. Fabricant PD, Bedi A, La Torre De K, et al. Clinical outcomes after arthroscopic psoas lengthening: the effect of femoral version. *Arthroscopy* 2012;28(7):965–71.

47. Hwang D-S, Hwang J-M, Kim P-S, et al. Arthroscopic treatment of symptomatic internal snapping hip with combined pathologies. *Clin Orthop Surg* 2015;7(2): 158–63.
48. Wettstein M, Jung J, Dienst M. Arthroscopic psoas tenotomy. *Arthroscopy* 2006; 22(8):907.e1–4.
49. Byrd JWT. Evaluation and management of the snapping iliopsoas tendon. *Instr Course Lect* 2006;55:347–55.
50. Ilizaliturri VM Jr, Villalobos FE Jr, Chaidez PA, et al. Internal snapping hip syndrome: treatment by endoscopic release of the iliopsoas tendon. *Arthroscopy* 2005;21(11):1375–80.
51. Ilizaliturri VM Jr, Buganza-Tepole M, Olivos-Meza A, et al. Central compartment release versus lesser trochanter release of the iliopsoas tendon for the treatment of internal snapping hip: a comparative study. *Arthroscopy* 2014;30(7):790–5.
52. Ilizaliturri VM, Chaidez C, Villegas P, et al. Prospective randomized study of 2 different techniques for endoscopic iliopsoas tendon release in the treatment of internal snapping hip syndrome. *Arthroscopy* 2009;25(2):159–63.
53. Hain KS, Blankenbaker DG, De Smet AA, et al. MR appearance and clinical significance of changes in the hip muscles and iliopsoas tendon after arthroscopic iliopsoas tenotomy in symptomatic patients. *HSS J* 2013;9(3):236–41.
54. Blomberg JR, Zellner BS, Keene JS. Cross-sectional analysis of iliopsoas muscle-tendon units at the sites of arthroscopic tenotomies: an anatomic study. *Am J Sports Med* 2011;39(Suppl):58S–63S.
55. Heyworth BE, Shindle MK, Voos JE, et al. Radiologic and intraoperative findings in revision hip arthroscopy. *Arthroscopy* 2007;23(12):1295–302.
56. Domb BG, Shindle MK, McArthur B, et al. Iliopsoas impingement: a newly identified cause of labral pathology in the hip. *HSS J* 2011;7(2):145–50.
57. Seldes RM, Tan V, Hunt J, et al. Anatomy, histologic features, and vascularity of the adult acetabular labrum. *Clin Orthop Relat Res* 2001;382:232–40.
58. Blankenbaker DG, De Smet AA, Keene JS, et al. Classification and localization of acetabular labral tears. *Skeletal Radiol* 2007;36(5):391–7.
59. Yoshio M, Murakami G, Sato T, et al. The function of the psoas major muscle: passive kinetics and morphological studies using donated cadavers. *J Orthop Sci* 2002;7(2):199–207.
60. Blankenbaker DG, Tuite MJ, Keene JS, et al. Labral injuries due to iliopsoas impingement: can they be diagnosed on MR arthrography? *AJR Am J Roentgenol* 2012;199(4):894–900.
61. Cascio BM, King D, Yen Y-M. Psoas impingement causing labrum tear: a series from three tertiary hip arthroscopy centers. *J La State Med Soc* 2013;165(2): 88–93.